

Investigation and Management of Periprosthetic Joint Infection in the Shoulder and Elbow: Evidence and consensus based guidelines of the British Elbow and Shoulder Society

Amar Rangan, Mark Falworth, Adam C Watts, Matthew Scarborough, Michael Thomas, Rohit Kulkarni and Jonathan Rees; On behalf of the BESS PJI Group

1. Introduction

1.1 Background

Periprosthetic Joint Infection (PJI) is a relatively rare but potentially devastating complication affecting shoulder and elbow joint arthroplasty. The increasing use of these procedures in the surgical management of arthritis and trauma means that the incidence of PJI is also likely to rise. The much larger burden of PJI in hip and knee arthroplasty has made international groups develop consensus definitions on diagnosis and guidance on investigations required to confirm PJI.^{1–3} Infection reported as a cause for revision within the UK National Joint Registry (NJR) currently is 0.27% for shoulder arthroplasty and 1.13% for elbow arthroplasty.⁴ Although the numbers of PJI are relatively low with shoulder and elbow arthroplasty the impact on patients, the treating surgical teams and healthcare resources remains significant.

Scoping reviews of the current body of literature on shoulder and elbow PJI confirmed a limited quality of published papers, mostly based on small retrospective case series and cohort studies.^{5,6} The British Elbow and Shoulder Society (BESS) has therefore developed these clinical guidelines on investigation and management of shoulder and elbow PJI by combining available evidence from the literature with consensus developed by a working group of BESS surgeons, infectious disease physicians and BESS physiotherapists.

1.2 Definition

PJI may occur either by contamination during surgery, by contiguous spread through adjacent tissue planes or by haematogenous spread of infection from another

source. We adopt the view that wound contamination during surgery by higher virulence organisms leads to PJI manifesting less than 3 months from surgery and contamination by lower virulence organisms leads to PJI manifesting between 3 months and 24 months from surgery. Late PJI manifesting more than 24 months from surgery is usually via haematogenous seeding, or less commonly by contiguous spread of infection, for example from surgery to adjacent tissues breaching healed tissue planes.

The diagnosis of PJI may be straightforward in some, but a complex process in others with little global consensus on the best approach to definitively confirm or exclude the diagnosis of infection. Diagnosis of PJI is usually made based on a combination of clinical, radiographic and intraoperative findings alongside blood results and microbiological cultures.⁷ Clinical diagnosis of PJI can be difficult, as low-grade infections may present with non-specific and vague symptoms such as pain and stiffness. Presence of a combination of clinical features that include pain, peri-articular warmth, erythema, effusion, and fever should raise the index of suspicion for PJI. These have been referred to as “clinical findings that raise or lower the pre-test probability of PJI”.⁸ Plain radiographs may demonstrate progressive radiolucent lines along the bone-prosthesis interface, other areas of osteolysis or osteopenia. These radiological features in isolation are non-specific, particularly in late PJI, where

United Kingdom of Great Britain and Northern Ireland

Corresponding author:

Amar Rangan, United Kingdom of Great Britain and Northern Ireland.
United Kingdom of Great Britain and Northern Ireland.
Email: amar.rangan@york.ac.uk

aseptic loosening may lead to similar findings. The role of advanced imaging modalities in diagnosis of PJI remains uncertain. Laboratory tests on peripheral blood, synovial fluid and periprosthetic tissue from the affected joint can help confirm diagnosis. It should be noted that C-Reactive Protein (CRP) and Erythrocyte Sedimentation Rate (ESR) measurements form only one part of the clinical assessment; and although they may contribute to the diagnostic pathway, they cannot be used in isolation. Diagnostic criteria have been developed by different international consensus groups, with high concordance demonstrated between the definitions recommended by the Musculoskeletal Infection Society (MSIS) and the Infectious Diseases Society of America (IDSA).⁹

Whilst there are no universally accepted guidelines for diagnosis, we recommend using the MSIS criteria,² which defines confirmation of PJI when any one of the main criteria (in bold) in Table 1 is present. We recommend this to be supplemented with histological examination where tissue from the affected joint is sampled. The presence of Leucocyte Esterase (LE) ++ in the synovial fluid, although found to be reliable in knee arthroplasty for diagnosis if PJI, has been found to be of doubtful value in shoulder arthroplasty.¹⁰

1.3 Shared decision making

The General Medical Council's 'Good Medical Practice – duties of a doctor' guide¹¹ clearly states in

the section on working in partnership with patients that doctors should:

- Listen to patients and respond to their concerns and preferences
- Give patients the information they want or need in a way they can understand
- Respect patients' right to reach decisions with the doctor about their treatment and care
- Support patients in caring for themselves to improve and maintain their health

This can only be achieved by direct consultation between the patient and their treating clinician. Decisions about treatment taken without such direct consultation between patient and treating clinician are not appropriate, as they do not adhere to principles of good medical practice.

2. Care Pathway

2.1 Aims of treatment

The overall treatment aim is based on early awareness of potential PJI, early referral to secondary care and subsequent potential onward referral for tertiary care. Treatment decisions can be complex, often require multidisciplinary treatment and success needs to be defined individually with patients in a shared decision making process.

2.2 Assessment in Primary Care & Community Triage Services

Having a high index of suspicion is important to prevent undue delay in optimum treatment for the patient. Plain radiographs of a suspected infected joint in such circumstances may not be useful and should not unduly delay referral.

Features to consider:

- Date of joint replacement
- Duration of symptoms – are they since surgery or sudden and new.
- Global reduction in range of motion, especially severe loss of passive movement
- Any signs of systemic upset or sources of infection
- Co-morbidities making the patient more susceptible to infection

2.3 Red Flags for same day emergency referral

A suspected infected joint needs same day urgent referral if an acute infection is suspected. Consider same day

Table 1. MSIS criteria for diagnosis of periprosthetic joint infection.

1. There is a sinus tract communicating with the prosthesis; or
2. A pathogen is isolated by culture from at least two separate tissue or fluid samples obtained from the affected prosthetic joint; or
3. Four of the following six criteria exist:
1. Elevated serum erythrocyte sedimentation rate (ESR) and serum C-reactive protein (CRP) concentration,
2. Elevated synovial fluid leukocyte count (>1100/μl),
3. Elevated synovial fluid neutrophil percentage (>65%),
4. Presence of purulence in the affected joint,
5. Isolation of a microorganism in one culture of periprosthetic tissue or fluid, or
6. Greater than five neutrophils per high-power field in five high-power fields observed from histologic analysis of periprosthetic tissue at ×400 magnification.

emergency referral for:

- Acute severe pain +/- redness +/- swelling after a recent joint replacement.
- Increasing/worsening pain in a recent joint replacement with features of systemic symptoms/illness.
- New acute severe pain +/- redness +/- swelling in a previously well-functioning joint replacement.
- Any increase in pain from a replaced joint if accompanying systemic symptoms/illness.

2.4 Indications for urgent referral within 2 weeks

Many PJI are chronic in nature with the patient being well but presenting over months with pain, poor function and gradual loosening and failure of the implant. Such patients do not require same day emergency referral but they do warrant prompt referral to the secondary care provider that carried out the joint replacement.

2.5 Treatment in Primary Care & Community Triage Services

Whilst shared decision-making is important, and individual patients' needs are different, prompt referral to secondary care is indicated.

If the patient is well (particularly if a chronic presentation) antibiotics should be avoided as this can be detrimental to optimum secondary care management which requires precise isolation of causative organisms. Specimens are therefore usually obtained before antibiotics are administered.

If an acute infection is present and the patient is unwell then emergency secondary care referral should be made as highlighted in the section above. Antibiotics should be discussed with the on-call orthopaedic team if in doubt.

3. Treatment in Secondary Care

3.1 Microbiology & Medical Management

3.1.1 General Principles. Effective management of PJI usually includes careful and complete surgical debridement and removal of all non-vital tissue. Where this is not possible, there is a substantially higher risk of treatment failure, irrespective of the choice or dose of antibiotic.¹² Under some circumstances, the aims of therapy may shift towards long-term suppression rather than cure. A clear operation note detailing the surgical findings and procedure, and close collaboration between the surgical team and infection specialists, are therefore indispensable for the optimal management of bone and joint infection.

3.1.2 Tissue sampling in secondary care. If there is clinical suspicion of infection, or persistent/progressive pain of unexplained origin, investigations for PJI are indicated. Joint aspiration should be considered in all patients with suspected infection irrespective of whether the implant is well fixed. Radiologically guided percutaneous biopsy may be indicated in certain circumstances. Examples include cases in which the diagnosis of infection cannot be confirmed clinically, cases in which surgery is not feasible but clinicians need to establish optimal directed suppressive therapy, or in cases where it is important to establish the choice of local antibiotic to be incorporated into cement or void filler at the time of operation. Where there is clear indication for surgery intra-operative tissue sampling should be performed in preference to pre-operative sampling. Examples of such cases include suspected infection with implant loosening, and debridement with implant retention in response to a definitive clinical diagnosis of infection with a well-fixed implant. For intra-operative sampling, five separate tissue samples for culture and two further samples for histology are the minimum recommended. Tissue samples should be obtained using a sampling set, which should include separate knives and forceps and sterile tissue pots for each of the samples. Synovial fluid, if sampled, should be added to aerobic and anaerobic blood culture bottles. Samples obtained should be subject to prolonged cultures for at least 8 days to detect presence of slow growing organisms. Specific requests for culture of mycobacteria, fungi and nocardia should be considered where epidemiological and clinical risk factors for these organisms exist.

3.1.3 Choice of antimicrobial agent. Although antibiotic guidelines are undoubtedly helpful, selection of the most appropriate agents necessarily has to be individualized, taking into consideration bacterial, host and drug factors. Bacterial factors include local epidemiology, antimicrobial susceptibilities and capacity for biofilm formation. For example, the presence of *Propionibacterium acnes* or *Staphylococci* in a patient undergoing Debridement, Antibiotics and Implant Retention (DAIR) would point towards inclusion of rifampicin in the treatment regimen because of its effectiveness in biofilm associated infection.¹³

Host factors that influence choice of antimicrobial agent include comorbidities, allergies and physiological status. For example, a patient with significant renal impairment might mandate avoidance or dose adjustment of potentially nephrotoxic antimicrobials. Drug factors, such as bioavailability, side effects, tissue or bone penetration, half-life and drug-drug interactions, also influence choice of antimicrobial agent. An example might be the avoidance of

ciprofloxacin in a patient taking other medications that prolong the QT interval.

Antimicrobial stewardship is an important overarching principle governing the choice of antimicrobial agent. Although it is common practice to employ broad spectrum agents immediately after surgical sampling, clinicians should switch to targeted therapy with the narrowest spectrum agent likely to be effective once susceptibilities of the causative pathogen are known. The surgeon should discuss the patient, organism and antibiotics with a specialist in clinical infection as part of the multidisciplinary management.

3.1.4 Dose of antimicrobial agents. Traditionally, treatment of bone and joint infection is considered to require high dose antibiotic therapy. This probably reflects the variation between agents in bone penetration. Beta-lactam antibiotics have relatively poor bone penetration and therefore, in order to achieve adequate levels at the site of infection, high dose therapy is required. Conversely, there are some agents such as doxycycline and rifampicin which achieve adequate concentration in bone with standard dosing regimens.

Periprosthetic joint infections are commonly characterized by the presence of biofilm-associated sessile bacteria in a stationary growth phase. This markedly increases the concentration of antibiotic required at the site of infection. For a minority of agents, therapeutic drug monitoring is used to inform the most appropriate dosage.

3.1.5 Route of antimicrobial administration. Although immediate post-operative antibiotic therapy is most commonly administered intravenously, there is increasing confidence in an early switch to oral therapy in the management of bone and joint infection.¹⁴ Its effectiveness relies on the selection of agents with adequate oral bioavailability and good bone penetration, as well as robust mechanisms to promote good adherence to therapy. Where these factors cannot be ensured, it may be appropriate to continue IV therapy. The advantages of oral therapy include reduced risk of complications associated with intravenous access devices, earlier discharge from hospital and reduced costs as compared to IV therapy.

3.1.6 Duration of antimicrobial therapy. Duration of therapy is poorly defined but influenced by several factors. Where surgery is considered completely curative, such as following amputation, there is probably no need for post-operative antibiotic therapy although it is common practice to include antibiotic cover for 24 – 48 hours. Following removal of an infected prosthetic joint without retention of any metalware or cement post-operatively, six weeks of systemic therapy is

probably adequate. Evidence for this includes a recent prospective trial in vertebral osteomyelitis which compared 12 weeks versus 6 weeks of therapy.¹⁵

For PJI managed by DAIR, observational data relating to 112 infected arthroplasties (which included only six upper limb joints) suggests that continuing therapy beyond 180 days is likely to postpone but not reduce the absolute risk of treatment failure following cessation of therapy.¹⁶ International guidelines for DAIR advocate pathogen-specific antibiotic durations of 3 and 6 months post-operatively for total hip and knee arthroplasties respectively. The guidelines suggest that upper limb PJI should be managed as for infected prosthetic hip joints¹. The evidence and reasons for this are limited and not all upper limb joints are similar to hip joints. As such we recommend that shoulder and elbow PJI treated by DAIR should receive 3 to 6 months of pathogen-specific antibiotics. The exact duration will be guided by the infection specialist, based on surgical clearance, organisms, sensitivities and choice of antibiotics.

3.1.7 Specific organisms

Staphylococcal infection-MSSA. Flucloxacillin is widely considered the optimal anti-staphylococcal agent where susceptibilities allow. The usual intravenous dose is 2 g QDS. It has variable oral bioavailability which limits its utility as an oral agent in PJI.

Ceftriaxone is an alternative intravenous agent for patients with non-anaphylactic penicillin allergy and for out-patient antimicrobial therapy (OPAT) given the convenience of once daily dosing (usually 2 g OD).¹⁷

Where oral therapy for staphylococcal infection is being considered, dual oral agents are preferred. These might include ciprofloxacin, doxycycline or cotrimoxazole most commonly in combination with rifampicin. The latter is particularly important in metalware associated infection managed by DAIR.

MRSA and coagulase negative staphylococci. Coagulase negative staphylococci are frequently resistant to methicillin and, even where they appear susceptible in vitro, their tendency to polyclonality means that they are often treated as methicillin resistant.

For methicillin-resistant *Staphylococcus aureus* (MRSA), vancomycin (with serum trough level 15-20 mg/L before the fourth dose) has long been the standard of treatment. Teicoplanin (12 mg/Kg and serum trough level 20-60 mg/L after a minimum of five days of therapy) is an alternative agent used for once-daily dosing in outpatient antimicrobial IV therapy settings.

Glycopeptide bactericidal ability and the clinical results obtained are suboptimal, especially in retention procedures. Alternative drugs such as daptomycin and

fosfomycin, often in combination with β -lactams, are being used increasingly but clear prospective evidence of their advantage is awaited.

Staphylococci are the archetypal biofilm associated organisms, especially in the context of PJI and device related infection. Where possible, the addition of adjunctive rifampicin should be considered but should not be used as monotherapy due to the high risk of resistance emergence. Although the optimal dose of rifampicin has not been determined, 300 mg BD appears to be effective. Rifampicin and a fluoroquinolone such as ciprofloxacin appears to be the most effective oral combination therapy in staphylococcal bone and joint infection. Where ciprofloxacin cannot be used, alternative oral agents include clindamycin, doxycycline, co-trimoxazole, linezolid, fusidic acid and pristinamycin. However, side effects, lack of pharmacokinetic data and the potential influence of enzyme induction by rifampicin mean that further prospective data are required before recommendation can be made in favor of one agent over the others.

Streptococcal infection. Antimicrobial therapy for Streptococcal PJI most commonly consists of a beta lactam. However, these agents have poor activity against bacteria in the stationary phase of growth so are they are poorly effective against biofilm. Recent studies demonstrate improved outcome with adjunctive rifampicin but this has yet to be confirmed.¹⁸

Infection caused by Enterococci. Outcome following enterococcal infection is often disappointing. Intravenous therapy is most commonly with a glycopeptide such as vancomycin or, in the case of *E. faecalis*, with amoxicillin. Alternatives include daptomycin, linezolid and tigecycline; addition of adjunctive rifampicin to these three agents reveal the best *in vitro* results. *E. faecalis* (but not *E. faecium*) is innately resistant to pristinamycin.

Infections caused by Gram negative rods. Beta-lactam antibiotic therapy is generally effective against susceptible organisms in the initial phase of growth. This may include a 3rd generation cephalosporin for sensitive Enterobacteriaceae, a carbapenem for ESBL and AMP-C beta-lactamase producing organisms, or an anti-pseudomonal beta-lactam for *P. aeruginosa*. For biofilm associated infection, ciprofloxacin is usually the treatment of choice provided the organism is susceptible and that there are no contraindications. Where this isn't possible, co-trimoxazole can be considered.¹⁹

Propionibacterium/Cutibacterium acnes infections. *P. acnes* is commonly isolated following upper limb

surgery. It is a ubiquitous skin commensal so distinguishing its presence as a contaminant versus pathogen requires careful correlation with clinical and histological findings. Due to its low virulence, there is often limited local inflammatory response and systemic markers such as CRP are frequently normal. It is usually susceptible to a range of narrow spectrum agents, including penicillin and doxycycline, so use of broad spectrum agents is rarely indicated. Clindamycin is recommended in international guidelines¹ but resistance rates are rising and may preclude its use. As *P. acnes* is associated with biofilm formation, the addition of adjunctive rifampicin is recommended particularly in metalware associated infection although its role is less clear than with other biofilm producing organisms.²⁰

3.1.9 Culture negative PJI. The incidence of culture negative infection is between 5 – 25%. Its diagnosis relies on clinical, radiological and histological findings. Antimicrobial management of culture negative PJI is guided primarily by local epidemiology, clinical history and prior antibiotic exposure. In the absence of any previous isolates, empiric therapy most commonly reflects treatment of staphylococcal infection. The combination of either ciprofloxacin or doxycycline with rifampicin would be reasonable examples for most European centres.

Where surgery is indicated for a failing arthroplasty and PJI is thought to be unlikely based on radiological appearance, normal blood parameters, and a negative joint aspirate culture, it is appropriate to proceed to either a one or two stage revision based on an informed discussion with the patient and taking in to account their wishes. In either circumstance biopsies should be obtained for microbiology and histology at the time of revision surgery.

3.2 Surgical decision making

3.2.1 Shoulder PJI. The evidence for the most suitable treatment regime for PJI following shoulder arthroplasty is currently poorly reported in the medical literature due to a low numbers and absence of multi-centre clinical trials where different treatment modalities are directly compared. However, there are essentially four options available to the clinician once infection is suspected or diagnosed. These include Debridement, Antibiotics and Implant Retention (DAIR), one stage revision, two stage revision and excision arthroplasty. The indications for each treatment option are different (Figure 1).

3.2.1a Debridement, Antibiotics and Implant Retention (DAIR). There is little role for the sole use of long term antibiotic suppressive therapy in the management

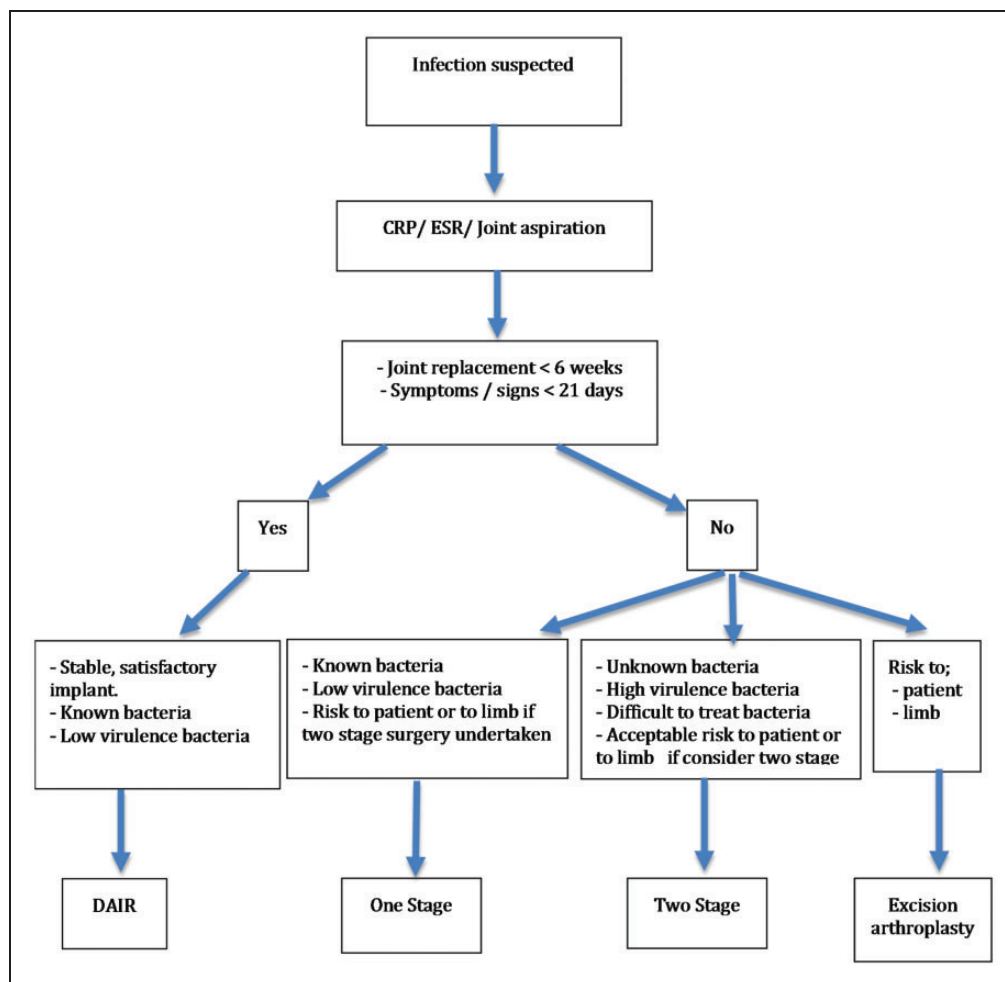


Figure 1. Basic Treatment Algorithm for Shoulder PJI.

of PJI. Although it may be indicated in those patients who are medically too compromised to consider surgery, its failure rates are high. However, DAIR may be useful in those cases of PJI where early infection is identified, however the long-term use of suppressive antibiotics may still be necessary.²¹ DAIR and open biopsy, could also be considered in the management of the painful arthroplasty where all other potential causes of pain, apart from occult infection, have been excluded and all previous investigations have proven unremarkable. However, it is important to note that whilst elevated blood parameters (ESR/CRP) can prove helpful in monitoring some infections, normal results do not exclude the presence of infection.

Early PJI can be defined as when infection is identified within six weeks of surgery and in those patients who have only experienced symptoms or signs of infection for up to three weeks. In such circumstances, appropriate cases for DAIR include those in which the implant is considered satisfactory and where the bacteria can be identified and are of low virulence. Antibiotic treatment

should be withheld until operative specimens are taken, in the manner previously described, following which a thorough open debridement is undertaken with the exchange of any modular components where applicable. Arthroscopic debridement alone has been described, but the outcome is questionable.^{22,23} Postoperative antibiotic management should then be managed with the aid of a Microbiology Multi-Disciplinary Team (MDT) and, if necessary, Outpatient Parenteral Antibiotic Therapy (OPAT) teams.

3.2.1b One Stage. There is little written in the medical literature comparing one-stage to two-stage revision and, further work is needed to determine the efficacy of each of these techniques in the management of PJI. However, although infection eradication has been reported, there is a greater risk of persistent pain and complications when a one-stage revision is undertaken compared to when a two-stage revision is utilised.^{24,25}

The indications for a one-stage revision are where the bacterium is known to be of low virulence or

easily treatable; and where multiple operative procedures are contra-indicated due to risk to patient and/or the limb.

The technique should also follow good practice previously outlined with early Microbiology MDT involvement and with the use of tissue sampling techniques for microbiology and histology sampling. Once the specimens have been taken and the implants (and where applicable the cement) have been removed, empirical treatment with antibiotics can be administered. A thorough debridement and lavage should be performed prior to insertion of the definitive implants, which if cemented, should be done so with a gentamicin impregnated cement. Other antibiotics may be added at the advice of your microbiologist.

The Microbiology MDT should coordinate the administration of the relevant antibiotics in the immediate postoperative period and, if appropriate, with the aid of the Outpatient Parenteral Antibiotic Therapy (OPAT) team. If infection still continues despite this, a two stage revision or excision arthroplasty could be considered.

3.2.1c Two Stage. The indications for a two-stage revision may be driven primarily by surgical preference. However, when the bacterium involved is not known or if known, is highly virulent, such that eradication might prove difficult, a two-stage revision is preferred. In undertaking a two-stage revision, the risks of multiple surgical procedures must be medically acceptable to the patient and the shoulder should be able to tolerate the multiple procedures whilst still delivering function. Notwithstanding this, two-stage revision is considered the most reproducible way to deliver the eradication of infection whilst also achieving good clinical outcomes.^{26,27}

The implant should be removed in the same manner as outlined in the one-stage technique. Once sampling and adequate debridement have been undertaken, intra-operative systemic antibiotics should be administered as defined by the Microbiology MDT; antibiotic impregnated spacers may be placed to maintain the joint space and deliver antibiotic treatment. Empirical systemic antibiotics should be continued in the post-operative period until antibiotic sensitivities are known. The infection team should coordinate the dose and mode of delivery of the antibiotic treatment. Following the completion of the treatment, usually after six weeks, the patient should remain off antibiotics for a minimum of two weeks to allow any residual infection to declare itself if present. If the patient remains asymptomatic, and clinical assessment is satisfactory, then the second stage can proceed. If investigations are abnormal and/or the patient is still symptomatic, then a radiologically guided joint aspiration, or possibly needle synovial biopsy, can

be performed prior to repeating antibiotic treatment with or without a further formal open debridement and repeat biopsy. The cycle then continues until the second stage of implant exchange is undertaken (Figure 2).

As in a one-stage technique, the Microbiology MDT and OPAT teams should coordinate all postoperative antimicrobial management. If positive cultures are unexpectedly grown following a second stage revision, then the appropriate antibiotic regime should be pursued whilst also considering another revision if the symptoms merit further intervention.

3.2.1d Excision Arthroplasty +/- spacer. The role of an excision arthroplasty is primarily aimed at those patients whose overall health would prevent them from undertaking prolonged or two-stage surgery or when the virulence of the organisms are such that repeated surgical interventions would be considered unwise to the overall health of the patient or to the viability of the arm. With no retained implant there is a good chance of the eradication of the infection, which may address some of the pain attributed to PJI, although there is a significant risk of functional impairment.^{27,28} Antibiotic impregnated spacers can also be used but these may still have to be removed at a later date.

3.2.2 Elbow PJI. The risk of infection after total elbow arthroplasty is increased in those of younger age, prolonged surgery, multiple previous surgeries and a diagnosis of inflammatory arthropathy.²⁹⁻³² A patient with an elbow arthroplasty with proven infection, or in whom infection is thought highly likely using the criteria outlined in Table 1, should be advised of the diagnosis and all the options for treatment so that an individualized plan can be formulated through shared decision making.

The treatment options considered should include debridement and implant retention, two stage revision, resection arthroplasty or antibiotic suppression. The last of these options may be appropriate for a patient who is systemically well, has well fixed implants infected with a known organism that responds to oral antibiotic therapy and for whom the risks of surgery outweigh the benefits.

3.2.2a Classification. Infected elbow arthroplasty can be classified using the system of Yamaguchi et al.³³ that aids treatment planning:

- (I) Infection with stable implant
- (II) Infection with unstable implants and adequate bone stock
- (III) Infection with poor bone stock that prevents reimplantation.

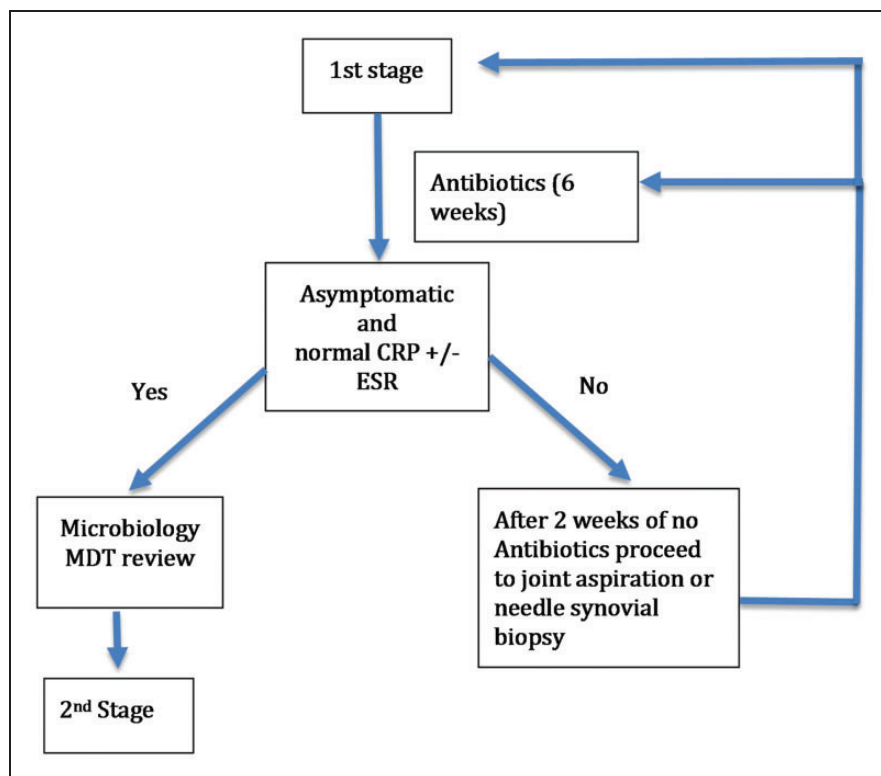


Figure 2. Basic algorithm for two-stage revision.

3.2.2b Debridement, Antibiotics and implant retention (DAIR). DAIR should be considered in patients with Yamaguchi type 1 infected elbow arthroplasty within three months of implantation and with a duration of symptoms of less than three weeks. The soft tissue cover should be good and the organism should be sensitive to antibiotics active against biofilms.³⁴ Surgery should be performed in an appropriate facility with expertise in the management of infected elbow arthroplasty. The surgery should include biopsy as outlined above, radical debridement to remove any necrotic or obviously infected soft tissue and exchange of all elements of the prosthesis that can be removed without stem extraction. This should include all bushing and humeral spools where possible. Thorough lavage with at least 6 litres of saline should be performed before exchange.³⁵

3.2.2c Two stage revision. For patients with Yamaguchi type 1 infected elbow arthroplasty not meeting the criteria for DAIR and those with Yamaguchi type 2 infection with a loose implant a two-stage revision should be considered. The surgery should include biopsy, meticulous sampling and debridement of the soft tissues, removal of the implants and all the cement using osteotomes, power burrs, curettes and an ultrasound device if needed.³⁶ Windowing of the bones may be required for well-fixed implants. Copious lavage with 6 litres of saline should be performed and an antibiotic laden

cement spacer inserted. Further surgical debridement may be required if signs of infection persist or the soft tissue contamination is severe.

The second stage of reimplantation can be performed a minimum of three months after the last surgical debridement as long as the patient does not meet any of the criteria in Table 1 to raise suspicion of ongoing infection. The patient should have been free from antibiotic treatment with no clinical recurrence for a period of four to six weeks prior to reimplantation. Repeat biopsy or aspiration prior to reimplantation may be considered.

If positive cultures are unexpectedly grown following a second stage revision, then the appropriate antibiotic regime should be pursued whilst also considering another revision if the symptoms merit further intervention.

3.2.2d Resection arthroplasty. A patient with a Yamaguchi type 3 infected elbow with bone stock inadequate to permit re-implantation may be considered for radical debridement of infected and necrotic tissue, removal of all implants and cement, and copious lavage with saline.³⁷ This is most likely to be successful in cases where both columns of the humerus are preserved. The elbow should be placed in to a cast or static splint at 90 degrees of elbow flexion for a period of six weeks. Skeletal reconstruction with allograft may be an option to permit reimplantation but there is

insufficient evidence to recommend this without further research.

3.2.2e One stage revision. We have deliberately listed this as the last surgical option for Elbow PJI. There is insufficient evidence in the literature to recommend single stage revision although there may be rare circumstances where it is considered in the best interest of the patient.³⁸ Any decision to perform a single stage revision will require multi-disciplinary team discussion and should only be considered in rare instances where a two stage revision is not in the best interest of the patient and the infection is known to be caused by a low virulence organism with known sensitivities. The decision should balance the risks of a two stage surgery against the risk of recurrent infection following a single stage revision and the need for revision implant removal, with the potential for additional bone loss that may prevent further re-implantation.

3.3 Resources needed for peri-operative care

Revision surgery should be performed in designated centres that have appropriate on-site support. The centre should have all the appropriate equipment available, to avoid additional loan costs. Immediate and reasonable access to relevant multi-disciplinary teams is important, specifically vascular surgery, plastic surgery and infectious diseases teams. Appropriate specialist rehabilitation services should be made available for patients undergoing revision surgery. Such rehabilitation may be undertaken closer to home if necessary.

4 Outcome Metrics

The following metrics should be routinely recorded by any centre managing shoulder and elbow PJI. Contributing data and cases to the National Joint Registry (NJR) is mandatory.

- Length of stay
- Re-admission rate within 30 days
- Mortality rates
- PROM pre-revision procedure, and minimum 6 months post procedure
- Revision data/conversion data and PROMS to be entered into the National Joint Registry
- Recurrent infection/complications/other adverse events
- Further revision prosthetic procedures

We have recommended a list of auditable standards for use by centres managing shoulder and elbow PJI, which are listed in Appendix 1

4.1 Coding and Finance

Appropriate diagnostic and procedural coding of procedures is vital for correct HRG mapping and for accurate data collection. For best practice in coding it is important for clinicians to engage with trained coders to ensure that all clinical coding standards are followed. It is also critical that all complications and comorbidities (CCs) are recorded. The current HRG4+ system is very granular and payment is dependent on the number of CCs.

The most common diagnostic and procedural codes for PJI are listed in Appendix 2. Also listed are the base HRGs that the procedures map to. The precise HRG will be determined by a number of factors including the number of complications and comorbidities.

Appropriate remuneration of actual costs for this specialist service provision is critical. Such service reconfiguration must not be delivered at negative cost to the centre and funds will need to follow service delivery. With an increasing workload, it is important that adequate and appropriate funding is provided to the centre in order to cover the additional resource costs for staffing, training, theatre and ward costs, equipment and rehabilitation.

Declaration of Conflicting Interests

The author(s) declared no potential conflicts of interest with respect to the research, authorship, and/or publication of this article.

Funding

The author(s) received no financial support for the research, authorship, and/or publication of this article.

References

1. Osmon DR, Berbari EF, Berendt AR, et al. Diagnosis and management of prosthetic joint infection: clinical practice guidelines by the Infectious Diseases Society of America. *Clinical infectious diseases: an official publication of the Infectious Diseases Society of America* 2013; 56: e1–e25. 10.1093/cid/cis803.
2. Parvizi J, Zmistowski B, Berbari EF, et al. New Definition for Periprosthetic Joint Infection: From the Workgroup of the Musculoskeletal Infection Society. *Clinical Orthopaedics and Related Research* 2011; 469: 2992–4.
3. Oussedik S, Gould K, Stockley I and Haddad FS. Defining peri-prosthetic infection. *Do we have a workable gold standard?* 2012; 94-B: 1455–6. 10.1302/0301-620x.94b11.30244. <http://bjj.boneandjoint.org.uk/content/jbjsbr/94-B/11/1455.full.pdf>.
4. National Joint Registry for England, Wales, Northern Ireland and Isle of Man. 14th Annual Report. 2017. <http://www.njrreports.org.uk/Portals/0/PDFdownloads/NJR14thAnnualReport2017.pdf>.

5. Egglestone A, Ingoe H, Jeavons R, Thomas M, Rees J and Rangan A. Scoping review: Diagnosis and management of peri-prosthetic joint infection in shoulder arthroplasty. (Paper under peer review for publication) 2017.
6. Watts A, Trail I, Thomas M, Rees K and Rangan A. Scoping review: Diagnosis and management of peri-prosthetic joint infection in elbow arthroplasty. (Paper under peer review for publication) 2017.
7. Bonneville N, Dauzeres F, Toulemonde J, Elia F, Laffosse JM and Mansat P. Periprosthetic shoulder infection: an overview. *EFORT Open Reviews* 2017; 2: 104–9. <https://www.ncbi.nlm.nih.gov/pmc/articles/PMC5420823/pdf/eor-2-104.pdf>.
8. Tsaras G, Osmon DR, Mabry T, et al. Incidence, secular trends, and outcomes of prosthetic joint infection: a population-based study, olmsted county, Minnesota, 1969–2007. *Infect Control Hosp Epidemiol* 2012; 33: 1207–12. 10.1086/668421.
9. Melendez DOD, Greenwood-Quaintance K, Hanssen AD, Patel R. Comparison of the Musculoskeletal Infection Society and Infectious Diseases Society of America diagnostic criteria for prosthetic joint infection. IDWeek 2013. San Francisco, 2013.
10. Nelson GN, Paxton ES, Narzikul A, Williams G, Lazarus MD and Abboud JA. Leukocyte esterase in the diagnosis of shoulder periprosthetic joint infection. *J Shoulder Elbow Surg* 2015; 24: 1421–6.
11. General Medical Council. Good Medical Practice. 2013. https://www.gmc-uk.org/guidance/good_medical_practice.asp.
12. Waldvogel FA, Medoff G and Swartz MN. Osteomyelitis: a review of clinical features, therapeutic considerations and unusual aspects. *N Engl J Med* 1970; 282: 198–206. 10.1056/nejm197001222820406.
13. Furustrand Taffin U, Corvec S, Betrisey B, Zimmerli W and Trampuz A. Role of rifampin against *Propionibacterium acnes* biofilm in vitro and in an experimental foreign-body infection model. *Antimicrob Agents Chemother* 2012; 56: 1885–91. 10.1128/aac.05552-11.
14. Conterno LO and Turchi MD. Antibiotics for treating chronic osteomyelitis in adults. *The Cochrane database of systematic reviews* 2013; 9: Cd004439. 10.1002/14651858.CD004439.pub3.
15. Bernard L, Dinh A, Ghout I, et al. Antibiotic treatment for 6 weeks versus 12 weeks in patients with pyogenic vertebral osteomyelitis: an open-label, non-inferiority, randomised, controlled trial. *Lancet* 2015; 385: 875–82. 10.1016/s0140-6736(14)61233-2.
16. Byren I, Bejon P, Atkins BL, et al. One hundred and twelve infected arthroplasties treated with ‘DAIR’ (debridement, antibiotics and implant retention): antibiotic duration and outcome. *J Antimicrob Chemother* 2009; 63: 1264–71. 10.1093/jac/dkp107.
17. Wieland BW, Marcantoni JR, Bommarito KM, Warren DK and Marschall J. A retrospective comparison of ceftriaxone versus oxacillin for osteoarticular infections due to methicillin-susceptible *Staphylococcus aureus*. *Clinical infectious diseases: an official publication of the Infectious Diseases Society of America* 2012; 54: 585–90. 10.1093/cid/cir857.
18. Lora-Tamayo J, Senneville E, Ribera A, et al. The Not-So-Good Prognosis of Streptococcal Periprosthetic Joint Infection Managed by Implant Retention: The Results of a Large Multicenter Study. *Clinical infectious diseases: an official publication of the Infectious Diseases Society of America* 2017; 64: 1742–52. 10.1093/cid/cix227.
19. Hsieh P-H, Lee MS, Hsu K-Y, Chang Y-H, Shih H-N and Ueng SW. Gram-negative prosthetic joint infections: risk factors and outcome of treatment. *Clinical Infectious Diseases: An Official Publication Of The Infectious Diseases Society Of America* 2009; 49: 1036–43. 10.1086/605593. <http://search.ebscohost.com/login.aspx?direct=true&db=cmedm&AN=19691430&site=ehost-live>.
20. Bayston RNB, Ashraf W and Freeman BJ. Antibiotics for the eradication of *Propionibacterium acnes* biofilms in surgical infection. *Antimicrob Chemother* 2007; 60: 1298–301.
21. Dennison T, Alentorn-Geli E, Assenmacher AT, Sperling JW, Sanchez-Sotelo J and Cofield RH. Management of acute or late hematogenous infection after shoulder arthroplasty with irrigation, debridement, and component retention. *J Shoulder Elbow Surg* 2017; 26: 73–8.
22. Jeon I, Choi C, Seo J, Seo K, Ko S and Park J. Arthroscopic management of septic arthritis of the shoulder joint. *J Bone Joint Surg Am* 2006; 88: 1802–6.
23. Sperling JW, Kozak TK, Hanssen AD and Cofield RH. Infection after shoulder arthroplasty. *Clinical Orthopaedics And Related Research* 2001; 382: 206–16. <http://search.ebscohost.com/login.aspx?direct=true&db=cmedm&AN=11153989&site=ehost-live>.
24. Ince A, Seemann K, Frommelt L, Katzer A and Loehr JF. One-stage exchange shoulder arthroplasty for periprosthetic infection. *J Bone Joint Surg Br* 2005; 87: 814–8 <http://bjj.boneandjoint.org.uk/content/jbjsbr/87-B/6/814.full.pdf>.
25. Assenmacher AT, Alentorn-Geli E, Sanchez-Sotelo J, Cofield RH and Sperling JW. Two-stage reimplantation for the treatment of deep infection after shoulder arthroplasty. *Journal of Shoulder and Elbow Surgery* 2005; 26: e163.
26. Sabesan VJ, Ho JC, Kovacevic D and Iannotti JP. Two-stage reimplantation for treating prosthetic shoulder infections. *Clin Orthop Relat Res* 2011; 469: 2538–43. https://www.ncbi.nlm.nih.gov/pmc/articles/PMC3148358/pdf/11999_2011_Article_1774.pdf.
27. Braman JP, Sprague M, Bishop J, Lo IK, Lee EW and Flatow EL. The outcome of resection shoulder arthroplasty for recalcitrant shoulder infections. *J Shoulder Elbow Surg* 2006; 15: 549–53.
28. Rispoli DMSJ, Athwal GS, Schleck CD and Cofield RH. Pain relief and functional results after resection arthroplasty of the shoulder. *J Bone Joint Surg Br* 2007; 89: 1184–7.
29. Toulemonde J, Ancelin D, Azoulay V, Bonneville N, Rongieres M and Mansat P. Complications and revisions after semi-constrained total elbow arthroplasty: a

- mono-centre analysis of one hundred cases. *Int Orthop* 2016; 40: 73–80. 10.1007/s00264-015-3008-z.
30. Morrey BF and Bryan RS. Infection after total elbow arthroplasty. *J Bone Joint Surg Am* 1983; 65: 330–8.
 31. Wolfe SW, Figgie MP, Inglis AE, Bohn WW and Ranawat CS. Management of infection about total elbow prostheses. *J Bone Joint Surg Am* 1990; 72: 198–212.
 32. Jeon I-H, Morrey BF, Anakwenze OA and Tran NV. Incidence and implications of early postoperative wound complications after total elbow arthroplasty. *Journal Of Shoulder And Elbow Surgery* 2011; 20: 857–65. 10.1016/j.jse.2011.03.005. <http://search.ebsco-host.com/login.aspx?direct=true&db=cmedm&AN=21641829&site=ehost-live>.
 33. Yamaguchi K, Adams RA and Morrey BF. Infection after total elbow arthroplasty. *J Bone Joint Surg Am* 1998; 80: 481–91.
 34. Achermann Y, Vogt M, Spormann C, et al. Characteristics and outcome of 27 elbow periprosthetic joint infections: results from a 14-year cohort study of 358 elbow prostheses. *Clinical Microbiology and Infection* 2011; 17: 432–8. 10.1111/j.1469-0691.2010.03243.x. <http://dx.doi.org/10.1111/j.1469-0691.2010.03243.x>.
 35. Spormann C, Achermann Y, Simmen BR, et al. Treatment strategies for periprosthetic infections after primary elbow arthroplasty. *J Shoulder Elbow Surg* 2012; 21: 992–1000. 10.1016/j.jse.2011.10.007.
 36. Peach CA, Nicoletti S, Lawrence TM and Stanley D. Two-stage revision for the treatment of the infected total elbow arthroplasty. *Bone Joint J* 2013; 95-b: 1681–6. 10.1302/0301-620x.95b12.31336.
 37. Rhee YG, Cho NS, Park JG and Song JH. Resection arthroplasty for periprosthetic infection after total elbow arthroplasty. *J Shoulder Elbow Surg* 2016; 25: 105–11. 10.1016/j.jse.2015.08.045.
 38. Gille J, Ince A, González O, Katzer A, Loehr JF. Single-stage revision of peri-prosthetic infection following total elbow replacement. *J Bone Joint Surg Br.* 2006;88(10): 1341–6.

Appendix I: Auditable recommendations for treatment of Periprosthetic Joint Infection in the Shoulder and Elbow in secondary care

1. Documented evidence of shared decision making for treatment tailored to the patient's wishes.
 2. Documented evidence of MDT discussion with an infection specialist.
 3. Intraoperative tissue sampling for infection includes a minimum of five tissue biopsies using separate scalpel, forceps and pots plus a further two samples for histology.
 4. Samples should be cultured for a minimum of eight days.
 5. Broad spectrum antibiotics are rationalised as soon as possible after microbiology sensitivities are available and following discussion with an infection specialist.
6. For DAIR, pathogen-specific antibiotics should be continued for between three and six months.
 7. For revision arthroplasty:
 - a DAIR is usually only considered in patients presenting with a stable implant within six weeks of surgery and in those patients who have had symptoms and signs of infection for only up to three weeks unless patient factors and co-morbidities preclude major complex revision surgery.
 - b One stage revision is only considered when the organism is known and of low virulence or where patient factors preclude a two-stage procedure
 - c In two stage arthroplasty antibiotics are given for a minimum of six weeks followed by a fallow period of at least two weeks before repeat testing or second stage.
 8. Centre has access to vascular surgery, plastic surgery and infectious disease services.
 9. Specialist rehabilitation services are available for revision arthroplasty patients.
 10. Length of stay is prospectively recorded.
 11. Readmission rates within 30 days are prospectively recorded.
 12. Mortality rates within 365 days are prospectively recorded.
 13. PROMS are prospectively recorded pre-revision and at a minimum of six months post procedure.
 14. Revision data is entered in to the National Joint Registry.
 15. Data are prospectively recorded on recurrent infection, complications, further revision prosthetic procedures and other adverse events.

Appendix 2: Diagnostic and procedure codes and HRG mapping

ICD 10 Diagnostic codes**

Osteoarthritis of elbow and shoulder

- M19.0 Primary arthrosis of other joints
- M19.1 Post-traumatic arthrosis of other joints
- M19.2 Other secondary arthrosis

Rheumatoid arthritis of the elbow and shoulder

- M05 Seropositive rheumatoid arthritis
- M06.0 Seronegative rheumatoid arthritis
- M06.1 Adult-onset Still disease
- M06.4 Inflammatory polyarthropathy
- M08.0 Juvenile rheumatoid arthritis

For the ICD codes above you will need to add a site code as a fifth character.

For the elbow the site code is .2- Upper arm Includes humerus and elbow.

The site code for shoulder is .1 Shoulder region Includes clavicle, scapula, acromioclavicular, glenohumeral, sternoclavicular joint

For example:

M19.02 Primary arthrosis of other joints – elbow

M19.01 Primary arthrosis of other joints- Shoulder

Periprosthetic fracture (without an identified cause)

M96.6 Fracture of bone following insertion of orthopaedic implant, joint prosthesis, or bone plate

Periprosthetic fracture (with a traumatic cause)

M96.6 Fracture of bone following insertion of orthopaedic implant, joint

Prosthesis or bone plate

Plus the relevant code for type of trauma from Chapter XX - External causes of morbidity and mortality (The coders will help with this)

Intraoperative fractures (including intraoperative periprosthetic/peri-implant fractures)

A code from Chapter XIX Injury, poisoning and certain other consequences of external causes (S00-T98) that classifies the fractured bone

Y79.2 Orthopaedic devices associated with adverse incidents, prosthetic and other implants, materials and accessory devices

Example

S72.30 Fracture of shaft of femur

Y79.2 Orthopaedic devices associated with adverse incidents, prosthetic and other implants, materials and accessory devices

Aseptic loosening

T84.0 Mechanical complication of internal joint prosthesis

This includes breakdown (mechanical), displacement, malposition, obstruction, perforation, protrusion etc

Infection

T84.5 Infection and inflammatory reaction due to internal joint prosthesis

** ICD-10 Extract from the licence:

<https://isd.digital.nhs.uk/trud3/user/guest/group/61/pack/28/subpack/258/licences> ICD-10 codes, terms and text used by permission of WHO, from: International Statistical Classification of Diseases and Related Health Problems, Tenth Revision (ICD-10). Vols 1-3. Geneva, World Health Organization, 1992-2016

OPCS -4 codes***

Elbow replacement

O21 Total prosthetic replacement of elbow joint using cement

O21.1 Primary total prosthetic replacement of elbow joint using cement

O21.2 Conversion to total prosthetic replacement of elbow joint using cement

O21.3 Revision of total prosthetic replacement of elbow joint using cement

O21.4 Revision of one component of total prosthetic replacement of elbow joint using cement

O22 Total prosthetic replacement of elbow joint not using cement

O22.1 Primary total prosthetic replacement of elbow joint not using cement

O22.2 Conversion to total prosthetic replacement of elbow joint not using cement

O22.3 Revision of total prosthetic replacement of elbow joint not using cement

O22.4 Revision of one component of total prosthetic replacement of elbow joint not using cement

Lateral resurfacing replacement

W58.1 Primary resurfacing arthroplasty of joint

Z81.5 Elbow joint

Elbow hemiarthroplasty

W52.1 Primary prosthetic replacement of articulation of bone using cement NEC

W53.1 Primary prosthetic replacement of articulation of bone not using cement NEC

W53.3 Revision of prosthetic replacement of articulation of bone not using cement NEC

Z69.7 Lower end of humerus NEC

Shoulder replacement

W49 Prosthetic replacement of head of humerus using cement

W49.1 Primary prosthetic replacement of head of humerus using cement

W49.2 Conversion to prosthetic replacement of head of humerus using cement

W49.3 Revision of prosthetic replacement of head of humerus using cement

W49.4 Resurfacing hemiarthroplasty of head of humerus using cement

W49.0 Conversion from previous cemented prosthetic replacement of head of humerus

W50 Prosthetic replacement of head of humerus not using cement

W50.1 Primary prosthetic replacement of head of humerus not using cement

W50.2 Conversion to prosthetic replacement of head of humerus not using cement

W50.3 Revision of prosthetic replacement of head of humerus not using cement

W50.4 Resurfacing hemiarthroplasty of head of humerus not using cement

W50.0 Conversion from previous uncemented prosthetic replacement of head of humerus

W96 Total prosthetic replacement of shoulder joint using cement

W96.1 Primary total prosthetic replacement of shoulder joint using cement

W96.2 Conversion to total prosthetic replacement of shoulder joint using cement

W96.3 Revision of total prosthetic replacement of shoulder joint using cement

W96.4 Revision of one component of total prosthetic replacement of shoulder joint using cement

W96.5 Primary reverse polarity total prosthetic replacement of shoulder joint using cement

W96.6 Revision of reverse polarity total prosthetic replacement of shoulder joint using cement

W96.0 Conversion from total prosthetic replacement of shoulder joint using cement

W97 Total prosthetic replacement of shoulder joint not using cement

W97.1 Primary total prosthetic replacement of shoulder joint not using cement

W97.2 Conversion to total prosthetic replacement of shoulder joint not using cement

W97.3 Revision of total prosthetic replacement of shoulder joint not using cement

W97.4 Revision of one component of total prosthetic replacement of shoulder joint not using cement

W97.5 Primary reverse polarity total prosthetic replacement of shoulder joint not using cement

W97.6 Revision of reverse polarity total prosthetic replacement of shoulder joint not using cement

W97.0 Conversion from total prosthetic replacement of shoulder joint not using cement

O06 Hybrid prosthetic replacement of shoulder joint using cemented humeral component

O06.1 Primary hybrid prosthetic replacement of shoulder joint using cemented humeral component

O06.2 Conversion to hybrid prosthetic replacement of shoulder joint using cemented humeral component

O06.3 Revision of hybrid prosthetic replacement of shoulder joint using cemented humeral component

O06.0 Conversion from previous hybrid prosthetic replacement of shoulder joint using cemented humeral component

O07 Hybrid prosthetic replacement of shoulder joint using cemented glenoid component

O07.1 Primary hybrid prosthetic replacement of shoulder joint using cemented glenoid component

O07.2 Conversion to hybrid prosthetic replacement of shoulder joint using cemented glenoid component

O07.3 Revision of hybrid prosthetic replacement of shoulder joint using cemented glenoid component

O07.0 Conversion from previous hybrid prosthetic replacement of shoulder joint using cemented glenoid component

Change of polyethylene inserts

O23.4 Attention to total prosthetic replacement of joint NEC

Y03.6 Adjustment to prosthesis in organ NOC

Add site code to all

Z81.5 Elbow joint

Z81.4 Shoulder joint

Excision arthroplasty

W57.2 Primary excision arthroplasty of joint NEC

W57.3 Revision of excision arthroplasty of joint

W57.4 Conversion to excision arthroplasty of joint

Add site code to all

Z81.5 Elbow joint

Z81.4 Shoulder joint

Replacement of infected prosthetic joint replacement first stage

O23.4 Attention to total prosthetic replacement of joint NEC

Y03.7 Removal of prosthesis from organ NOC

W81.7 Insertion of therapeutic spacer into joint

Y70.3 First stage of staged operations NOC

Add site code

Z81.5 Elbow joint

Z81.4 Shoulder joint

Please note: Debridement must not be coded in addition when a joint spacer has been inserted following removal of the prosthesis.

Second stage

Insertion of like for like prosthesis

Relevant revision code from list above

Y71.1 Subsequent stage of staged operations NOC

Insertion of a different type of prosthesis

O21.0 Conversion from total prosthetic replacement of elbow joint using cement

Or

O22.0 Conversion from total prosthetic replacement of elbow joint not using cement

Y71.1 Subsequent stage of staged operations NOC

HRG mapping without CCs

O21 Total prosthetic replacement of elbow joint using cement

O21.1 Primary total prosthetic replacement of elbow joint using cement – **HN62**

O21.2 Conversion to total prosthetic replacement of elbow joint using cement – **HN86**

O21.3 Revision of total prosthetic replacement of elbow joint using cement – **HN86**

O21.4 Revision of one component of total prosthetic replacement of elbow joint using cement – **HN86**

O22 Total prosthetic replacement of elbow joint not using cement

O22.1 Primary total prosthetic replacement of elbow joint not using cement – **HN62**

O22.2 Conversion to total prosthetic replacement of elbow joint not using cement – **HN86**

O22.3 Revision of total prosthetic replacement of elbow joint not using cement – **HN86**

O22.4 Revision of one component of total prosthetic replacement of elbow joint not using cement – **HN86**

Lateral resurfacing replacement

W58.1 Primary resurfacing arthroplasty of joint

Z81.5 Elbow joint

HN62B

Elbow hemiarthroplasty

W52.1 Primary prosthetic replacement of articulation of bone using cement NEC – **HN62**

W53.1 Primary prosthetic replacement of articulation of bone not using cement NEC – **HN62**

W53.3 Revision of prosthetic replacement of articulation of bone not using cement NEC – **HN86**

Z69.7 Lower end of humerus NEC

Shoulder replacement

W49 Prosthetic replacement of head of humerus using cement

W49.1 Primary prosthetic replacement of head of humerus using cement – **HN52**

W49.2 Conversion to prosthetic replacement of head of humerus using cement – **HN86**

W49.3 Revision of prosthetic replacement of head of humerus using cement – **HN86**

W49.4 Resurfacing hemiarthroplasty of head of humerus using cement – **HN52**

W49.0 Conversion from previous cemented prosthetic replacement of head of humerus – **UZ01Z**

W50 Prosthetic replacement of head of humerus not using cement

W50.1 Primary prosthetic replacement of head of humerus not using cement – HN52

W50.2 Conversion to prosthetic replacement of head of humerus not using cement – HN86

W50.3 Revision of prosthetic replacement of head of humerus not using cement – HN86

W50.4 Resurfacing hemiarthroplasty of head of humerus not using cement – HN52

W50.0 Conversion from previous uncemented prosthetic replacement of head of humerus – UZ01Z

W96 Total prosthetic replacement of shoulder joint using cement

W96.1 Primary total prosthetic replacement of shoulder joint using cement – HN52

W96.2 Conversion to total prosthetic replacement of shoulder joint using cement – HN86

W96.3 Revision of total prosthetic replacement of shoulder joint using cement – HN86

W96.4 Revision of one component of total prosthetic replacement of shoulder joint using cement – HN86

W96.5 Primary reverse polarity total prosthetic replacement of shoulder joint using cement – HN52

W96.6 Revision of reverse polarity total prosthetic replacement of shoulder joint using cement – HN86

W96.0 Conversion from total prosthetic replacement of shoulder joint using cement – UZ01Z

W97 Total prosthetic replacement of shoulder joint not using cement

W97.1 Primary total prosthetic replacement of shoulder joint not using cement – HN52

W97.2 Conversion to total prosthetic replacement of shoulder joint not using cement – HN86

W97.3 Revision of total prosthetic replacement of shoulder joint not using cement – HN86

W97.4 Revision of one component of total prosthetic replacement of shoulder joint not using cement – HN86

W97.5 Primary reverse polarity total prosthetic replacement of shoulder joint not using cement – HN52

W97.6 Revision of reverse polarity total prosthetic replacement of shoulder joint not using cement – HN86

W97.0 Conversion from total prosthetic replacement of shoulder joint not using cement – UZ01Z

O06 Hybrid prosthetic replacement of shoulder joint using cemented humeral component

O06.1 Primary hybrid prosthetic replacement of shoulder joint using cemented humeral component – HN52

O06.2 Conversion to hybrid prosthetic replacement of shoulder joint using cemented humeral component – HN86

O06.3 Revision of hybrid prosthetic replacement of shoulder joint using cemented humeral component – HN86

O06.0 Conversion from previous hybrid prosthetic replacement of shoulder joint using cemented humeral component – UZ01Z

O07 Hybrid prosthetic replacement of shoulder joint using cemented glenoid component

O07.1 Primary hybrid prosthetic replacement of shoulder joint using cemented glenoid component – HN52

O07.2 Conversion to hybrid prosthetic replacement of shoulder joint using cemented glenoid component – HN86

O07.3 Revision of hybrid prosthetic replacement of shoulder joint using cemented glenoid component – HN86

O07.0 Conversion from previous hybrid prosthetic replacement of shoulder joint using cemented glenoid component – UZ01Z

Change of polyethylene inserts

O23.4 Attention to total prosthetic replacement of joint NEC

Y03.6 Adjustment to prosthesis in organ NOC **HN63**

Add site code to all –

Z81.5 Elbow joint

Z81.4 Shoulder joint

Excision arthroplasty

W57.2 Primary excision arthroplasty of joint NEC – **HN64**

W57.3 Revision of excision arthroplasty of joint – **HN63**

W57.4 Conversion to excision arthroplasty of joint – **HN86**

Add site code to all –

Z81.5 Elbow joint

Z81.4 Shoulder joint

Replacement of infected prosthetic joint replacement first stage

O23.4 Attention to total prosthetic replacement of joint NEC

Y03.7 Removal of prosthesis from organ NOC

W81.7 Insertion of therapeutic spacer into joint

Y70.3 First stage of staged operations NOC

Z81.5 Elbow joint

Z81.4 Shoulder joint

HN62B

Please note: Debridement must not be coded in addition when a joint spacer has been inserted following removal of the prosthesis.

Second stage

Insertion of like for like prosthesis

Relevant revision code from above

Y71.1 Subsequent stage of staged operations NOC

Insertion of a different type of prosthesis

O21.0 Conversion from total prosthetic replacement of elbow joint using cement – **UZ01Z**

Or

O22.0 Conversion from total prosthetic replacement of elbow joint not using cement – **UZ01Z**

Y71.1 Subsequent stage of staged operations NOC

Mapping

*** OPCS-4 Extract from the licence:

<https://isd.digital.nhs.uk/trud3/user/guest/group/61/pack/10/subpack/119/licences>

The OPCS Classification of Interventions and Procedures, codes, terms and text is Crown copyright (2016) published by Health and Social Care Information Centre, also known as NHS Digital and licensed under the Open Government Licence available at www.nationalarchives.gov.uk/doc/open-government-licence/open-government-licence.htm.

***BESS PJI Group:**

PJI Working Group: *Amar Rangan, Michael Thomas, Jonathan Rees, Mark Falworth, Adam Watts, Ro Kulkarni, Deborah Higgs, Steve Corbett, Richard Jeavons, David Morrissey, Steve Bale, Simon Robinson, Steve Drew, Ian Trail.*

PJI Consultation Group (attendees at BESS Arthroplasty Meeting in York 11 Oct 2017): *Mohammed Abdus-Samee, Stephen Aldridge, Sudhi Ankarath, Sunil Auplish, Jaime Candal-Couto, Jagannath Chakravarthy, David Clark, Dave Cloke, Alan Cooney, Paul Cowling, Richard Craig, Tom*

Dehler, Amanda Denton, Ahmed Eid, Simon Fogerty, Ben Gooding, Roy Harvey, Cameron Hatrick, Philip Holland, Helen Ingoe, Niel Kang, Nick Little, Addie Majed, Milad Masjedi, Tim Matthews, Saurabh Mehta, Marie Morgan, Rajesh Nanda, Vipul Patel, Mark Philipson, Sarah Rayner, Paul Robinson, Will Rudge, Zulfiqar Sadiq, Ayad Salmons, Harvinder Singh, James Tyler, Sam Vollans, Ben Walton, Matthew Walmsley, John Williams, Caroline Witney-Lagen, Phil Wright, Amit Bidwai, Stuart Hay, Val Jones, Thomas Tudor, Ian Trail, David Stanley.